

altogether closed: on the inner side is a hole—the Eustachian tube—leading from the tympanum down to the back of the nose. On the other side is an opening into the large mass of bone, shaped like a sugar loaf upside down, which you can all feel behind your ears, which is known as the mastoid process. Now comes the most important point of all: you will see that anything which crawled up the Eustachian tube would be able to get not only into the tympanum but also into the mastoid process: this latter is not solid bone, but is composed rather of a honeycomb-like nest of cells, the largest of which is called the mastoid antrum, and is about the size of a pea. In fact, the eustachian tube, tympanum, mastoid antrum, and mastoid cells are for practical purposes all one cavity.

In scarlet fever, germs actually do crawl up the Eustachian tube in this manner, and they

The second figure shows a temporal bone which has been sawn across through the tympanum and mastoid process; the mastoid antrum and cells have been scraped out so as to make one cavity; the tympanic membrane and two of the auditory ossicles are shown. The auditory meatus in this case would be pointing straight towards us out of the paper.

So much for the anatomy of the disease. What happens in practice is that in about 80 per cent. of scarlet fever patients, the ears are not affected at all; the germs do not get into the Eustachian tube to begin with.

In the remaining 20 per cent. a discharge is seen. The more "septic" a case is, the earlier, as a rule, does it start, and the greater likelihood is there of the mastoid process being affected. The affection of the ear is almost always painless; there is little or no earache,




Fig. 3.—Back of the Ear; Opening into Mastoid Tympanum.

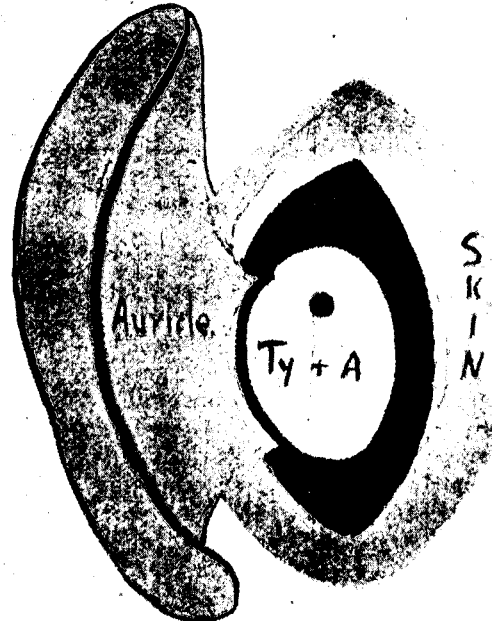


Fig. 4.—Back of the Ear. Cavity of the radical operation.

very soon reach the tympanum, and mastoid antrum also. What happens then? In the first place, matter is formed and collects in the tympanum until that cavity is full. It can then get out in three ways, either by bursting a way through the tympanic membrane, and so out through the auditory meatus (this we see every day when an ear discharges) or it can overflow into the antrum. There it is apt to collect, and an abscess in the mastoid process is the result. Or again, it sometimes bursts straight through the thin bony covering of the tympanum or antrum, and gives rise to an abscess in the coverings of the brain (meningitis) or in the brain itself.

and often the first thing noticed is that the patient's pillow is found to be stained with pus when he awakes in the morning. The tympanic membrane soon goes altogether, and it is a good thing that it does, because it would otherwise only obstruct the free drainage that is necessary. In about 15 out of these 20 per cent. of cases, the discharge gradually dries up, the membrane is replaced by scar tissue, and the patient recovers with sound ears and good or fair hearing.

In the remaining five, however, the result is much more serious; the pus may escape straight away through the roof of the tympanum, in which case the child dies of meningitis in a

[previous page](#)

[next page](#)